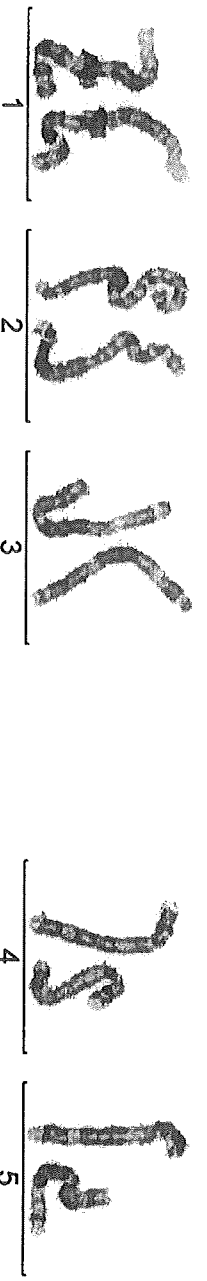
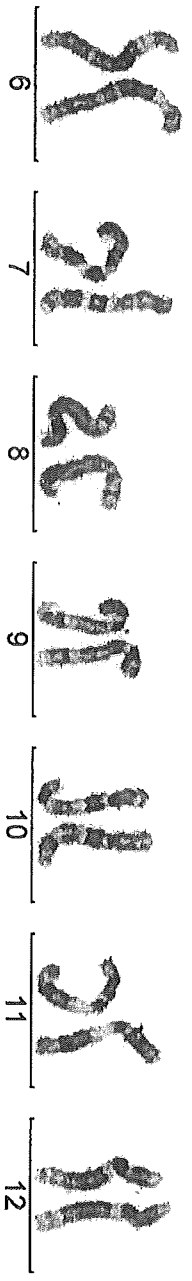


1 2 3 4 5




6 7 8 9 10 11 12



13 14 15 16 17 18



19 20 21 22 X Y



Nom del cas: 11cm0514  
Imatge: 006

Pacient: SP-11  
Carlotip: 46,XX

Data: 04/05/2011